

Imaging for Radiofrequency Ablation

Adubeiro Nuno¹, Pereira Daniel², Nogueira Luísa³, Pinho Ernesto⁴

^{1,2,3,4}Docente da área da Radiologia

Escola Superior de Tecnologia da Saúde do Porto, Portugal

¹*nca@estsp.ipp.pt*, ²*dap@estsp.ipp.pt*, ³*lpn@estsp.ipp.pt*, ⁴*efp@estsp.ipp.pt*

ABSTRACT

Many solid tumors have a poor response to systemic chemotherapy, local radiotherapy or surgical resection. They are responsible for premature morbidity and decreased patient survival.

The radiofrequency ablation is an emerging technique, and is now becoming more widespread throughout the world because it is minimally invasive, image guided, which offers the possibility of an effective and less costly approach.

The procedure can be performed percutaneously, guided by several imaging modalities as Ultrasound, Computed Tomography and Magnetic Resonance.

This article pretends to demonstrate the state-of-the-art of this technique focusing in the technical aspects and application of radiofrequency ablation.

Key words: radiofrequency, ablation, magnetic resonance, computed tomography

RESUMO

Muitos tumores sólidos têm uma fraca resposta à quimioterapia sistémica, resecção cirúrgica ou radioterapia local. São responsáveis por morbilidade prematura e diminuição da sobrevivência dos pacientes.

A termoablação por radiofrequência (ARF) é uma técnica emergente, minimamente invasiva, guiada por imagem, que oferece a possibilidade de uma abordagem eficaz e menos dispendiosa.

O procedimento pode ser realizado por via percutânea ou cirúrgica, guiado por várias modalidades imagiológicas tais como a Ecografia, Tomografia Computorizada e Ressonância Magnética.

O presente artigo pretende demonstrar o estado-da-arte desta técnica, centrando-se em aspectos técnicos e aplicações da ablação por radiofrequência.

Palavras-chave: radiofrequência, ablação, ressonância magnética, tomografia computadorizada

1. INTRODUCCION

Over time, many techniques have been developed in the context of tissue ablation. These same techniques include induction of high and / or very low temperatures (thermal ablation), radiation, chemotherapy, embolization (occlusion of blood supply to the tumor) injection of chemical agents, as well as various combinations of these methods. Although most of these have been introduced in the past century XX, at least one technique dates back to the century XIX. The basis of radiofrequency ablation (RFA) was released by Jacques D'Arsonval (1851-1940), who in 1891 showed for the first time, that when radio waves pass through a tissue, causing a temperature increase of that tissue. (Sonnenberg, 2005)

However, the use of RF for medical applications has become popular only with the introduction of a device created by Cushing and Bovie, which became known as "electrode Bovie" in 1928. This first generation of the electrodes were monopolar type, similar to those used today. The fact that RF causes an ionic agitation of the tissues surrounding the head of the electrode, was first demonstrated by Organ. Heat is produced in tissues, and this leads to clotting and cell necrosis. In 1993, he performed the first radiofrequency ablation of hepatic tumors in humans. Soon, this technique became widely available. (Sonnenberg,2005)

In simple terms, tumor ablation can be divided into two categories: chemical ablation and thermal ablation (or thermal ablation). Ablation chemical is classified by the chemical agent that is used in the process, such as ethanol (pure alcohol) or acid acetic.

The process of ablation that uses ethanol is more commonly known as "percutaneous ethanol instillation. For all types of chemical ablation, there are parameters to be set, for example, the route of administration (intravenous, intra-arterial or interstitial), the substance to be administered, the type and size of needles and / or catheters and the quantity to be administered. The category "thermal ablation" includes all sources of thermal energy capable of destroying a tumor, either by high temperatures (radiofrequency, laser, etc.) or negative temperatures (cryoablation). In general, the various types of thermal ablation techniques differ only in the physical process of generating heat. (Vogl,2008)

The ablation technique most commonly used and with greater number of procedures is radiofrequency ablation.

Radiofrequency ablation is now a generally accepted method for local tumor ablation and is most often used in liver and lung metastases and in primary renal cell carcinomas. It is also used in primary tumors (osteoid osteoma usually) and secondary bone and soft tissue metastases. It involves using a fairly simple equipment and inexpensive, but requires extensive experience of the operator and an appropriate selection of cases. The procedure can be performed percutaneously or surgery, and is driven by image. (Nicholson, 2009)

2. RADIOFREQUENCY ABLATION

2.1 Physical Principles

The fundamental principle of RFA is the biophysical interaction of an alternating current with biological tissues in terms of energy loss by resistance (or rubbing). Between the electrode and the electrode emission (scatter plate or return electrode - "Ground pad"), or between two electrodes issue in bipolar systems, is established an electric field that oscillates at frequency radio waves (radio frequency). (Kaufman,2004)

Thus, as is illustrated in Figures 1 and 2, in both cases it creates a closed circuit - in unipolar systems, by placing the generator in series, the electrode dispersion, the patient and the electrode emission; in bipolar systems between the generator, the patient and two electrodes arranged in parallel, with maximum distance between them of 3-4cm (in these systems, the dispersive electrode is replaced by a second emission electrode). (Vogl,2008)

The main characteristic of monopolar configuration is the high density energy field created by the electrode and relative power of penetration in depth in the tissue where it operates. This makes this type of emission the best suited to electro-surgery. (Vogl,2008)

In bipolar emission, current flows between two equal electrodes to a relatively small distance. This allows you to create a current of greater and easier control and distribution. Furthermore, with this system clotting is limited to the area between the two electrodes and this is achieved more quickly (approximately 5 minutes). Thus, the adjacent organs are protected. The limiting factor is that the penetration depth is decreased to half the distance between the electrodes of issue. (Vogl,2008)

The ionic agitation induced by this oscillating field results in heat, followed by coagulation and necrosis, if the energy applied is sufficient to do so, and the field strength directly affects the frequency of oscillation. Coagulation is achieved by induction of sources of electromagnetic energy below 900kHz. Most devices currently available have energies in the range of 375-500 kHz. (Vogl,2008)

Consequently, the tissues near the electrode heat. The thermal damage caused to tissues is dependent not only on the temperature reached locally, but also the duration of the process (time at which applies radio frequency), the design of the electrode, and factors intrinsic to the tissues (such as its thermal conductivity). The heat generated is directly proportional to the RF energy deposited, while the damage caused to the tissue is dependent on both the final temperature reached and the time interval that lasted warming. (Vogl,2008)

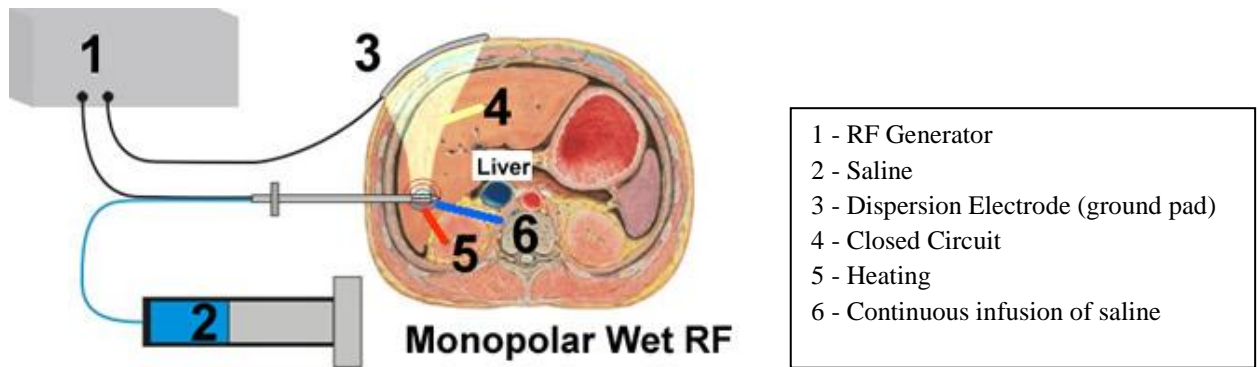


Figure 2 – representative diagram of a unipolar RF system

Source: <http://www.openradiology.org/zosirws/survey/bone%20metastasis%20radiofrequency/technique>

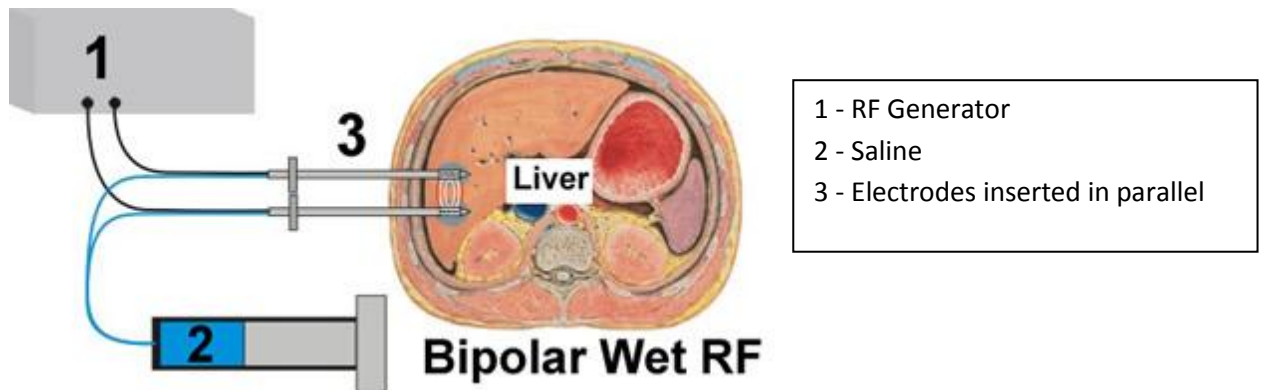


Figure 2 – representative diagram of a bipolar RF system

Source: <http://www.openradiology.org/zosirws/survey/bone%20metastasis%20radiofrequency/technique>

2.2 Image in the RFA process

Therapeutic procedures that require control by imaging, are used primarily to locate, access, monitorize and control the volume of target tissue, always trying to minimize collateral damage to surrounding tissues. (Kaufman, 2004; Vogl, 2008; Sonnenberg, 2005, Nicholson, 2009)

The location of the tumor is the initial step in a procedure for image guided thermal ablation. Occurs during the stages of diagnosis and planning of each case study.

The purpose is to identify and delineate the exact extent of the target tissue and adjacent anatomic structures.

For the correct location, not enough to define the margins of the tumor and adjacent anatomic structures, but rather, it is important to define the intra-tumor, for example, to differentiate the solid and cystic part to distinguish a tumor from a necrotic viable neoplastic tissue.

The contrast products play an essential role in characterizing the vasculature of a tumor and show their own borders.

Contrast examinations may characterize tumor perfusion, which is an essential information for thermal ablation.

The total destruction of most malignant tumors is practically unattainable due to the irregular contours and the same ill-defined and limited sensitivity of imaging methods used.

The failure of the techniques of thermal ablation is directly related to the inadequate definition of the target tissue. In fact, treatment is easier and more effective when the tumor is well located.

The products of contrast and tumor markers can improve not only the detection of tumors, but also the efficiency of thermal ablation.

In the access stage, the objective is to choose a path by which they gain access to the target tissue through the introduction of the electrodes.

Involves obtaining images during the actual procedure using imaging methods like x-ray fluoroscopy, computed tomography (CT) scan or magnetic resonance imaging (MRI), and sonography, which is the method most commonly used for this purpose.

Monitorize basically consists of measuring the temperature and the changes produced by temperature change in tissues as a result of deposition of RF. This monitoring allows the thermal ablation treatment to be effective, and at the same time, safe. Therefore, it is necessary that the imaging equipment have specific characteristics such as sensitivity to temperature variation tissue, good temporal resolution, ability to acquire volumetric images and ease of use for the operator.

The monitoring equipment in real time - fluoroscopy and ultrasound - imaging methods are inexpensive and relatively easy to handle, however, don't have sensitivity to thermal changes. Similarly, the TC does not show sensitivity to thermal changes. Only MR techniques are sensitive to changes in tissue temperature.

Parameters such as inversion time (TI), diffusion and chemical shift can be exploited to detect changes in temperature within a certain interval. Also, appropriate pulse sequences can differentiate phase transitions, the volume of tissue operated upon, and can reveal the contours of the lesions. Indeed, the role of MR imaging as a method in these procedures is twofold. First, real-time MR pulse sequences are sensitive to detect thermal changes of temperature elevations. Using this information, the operator may decide to discontinue the energy deposition, which may prevent undesirable heating of surrounding normal tissues. Moreover, MRI is able to show an irreversible tissue necrosis. For a safe and effective deposition of thermal energy, images should be obtained not only after the procedure, but also during the energy transfer.

The control phase is an extension of the monitoring. It is achieved by the interpretation of the effects seen. Requires an understanding of the relationship between reversible and irreversible thermal effects. Such control ensures that the physiological effects induced by high temperatures, such as vasodilatation, never reach a critical threshold.

2.2.1 Advantages and limitations of image methods

Sonography is widely available and usually allows easy access to the target lesion, visualization of the electrode and real-time assessment of the procedure. Furthermore it is portable. However, during the procedure, the target tissue can be obscured by microbubbles of gas which are formed by thermal effect, which does not allow highlighting the extent and size of coagulation necrosis and difficult to identify the electrode and the progression of it. Studies suggest that the use of sonographic contrast agent can eliminate this disadvantage. (Nicholson,2009)

The CT have the advantage of obtaining more information on the anatomical structures and pathology and the disadvantage of the lack of space inside the gantry (and consequent restriction of freedom of movement), by exposure to high doses of radiation and the need for the use of contrast product for visualization of the lesion to treat. (Nicholson,2009)

Another drawback is the inability to obtain sufficiently enlightening images before 12-18h post-ablation, since the first hours after the procedure, the CT image shows no enhancement in the ablated area, in contrast to what happens on an ultrasound. (Nicholson,2009)

Additionally, it is important to mention the high technical complexity inherent in this method of diagnosis and the high cost compared to ultrasound. (Nicholson,2009)

MRI is the only method able to give information about tissue changes caused by thermal effect. However, this feature - MR Thermometry - is more suitable for other modes as Focused Ultrasound Therapy and Laser Ablation, since only recently begun to be available RF electrodes compatible with MRI. (Nicholson,2009)

The general limitations of MRI are - similar to TC - high technical complexity, high costs and restricted freedom of movement by the operator. However, this type of equipment is characterized by having low magnetic fields (usually 0.2 to 0.5 T). (Nicholson,2009)

3. CLINICAL APPLICATIONS

The major applications of RF ablation are in the liver, kidneys, lungs and bone tumors. The techniques vary taking in account the localization of the lesion, the type of equipment used, and the skills of crew that are making the procedure. (Nicholson,2009) In the figures 3,4 and 5 are showed several types of RF ablation with image guided.

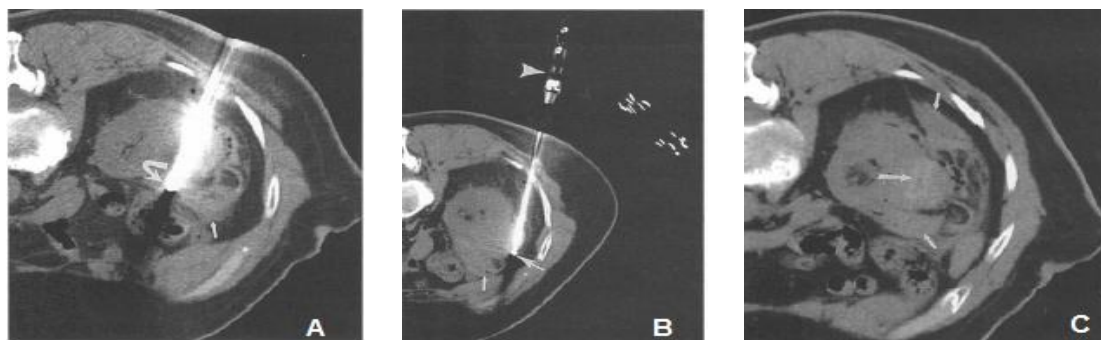


Figure 3 - CT during and immediately after RFA. (A) CT with the patient in prone position, shows electrode (curved arrow) near the medial margin of the tumor. A small amount of hemorrhage (small arrow) separates the tumor from the colon. (B) CT scan shows the electrode (arrow) repositioned in the lower lateral portion of the tumor. Again, we visualized a small amount of hemorrhage (small arrow) above. By positioning the patient for CT-guided RFA, the operator must leave enough space for the patient and to manage the electrode inside the gantry. (C) CT scan done after retired the electrodes and the end of four consecutive ablations, shows hemorrhage anterior and posterior to the kidney (small arrows). There are air adjacent to the tumor.

Source: Sonnenberg, E., McMullen, W., Solbiati (2005). *Tumor Ablation Principles and Practice*. Nova York. Springer.

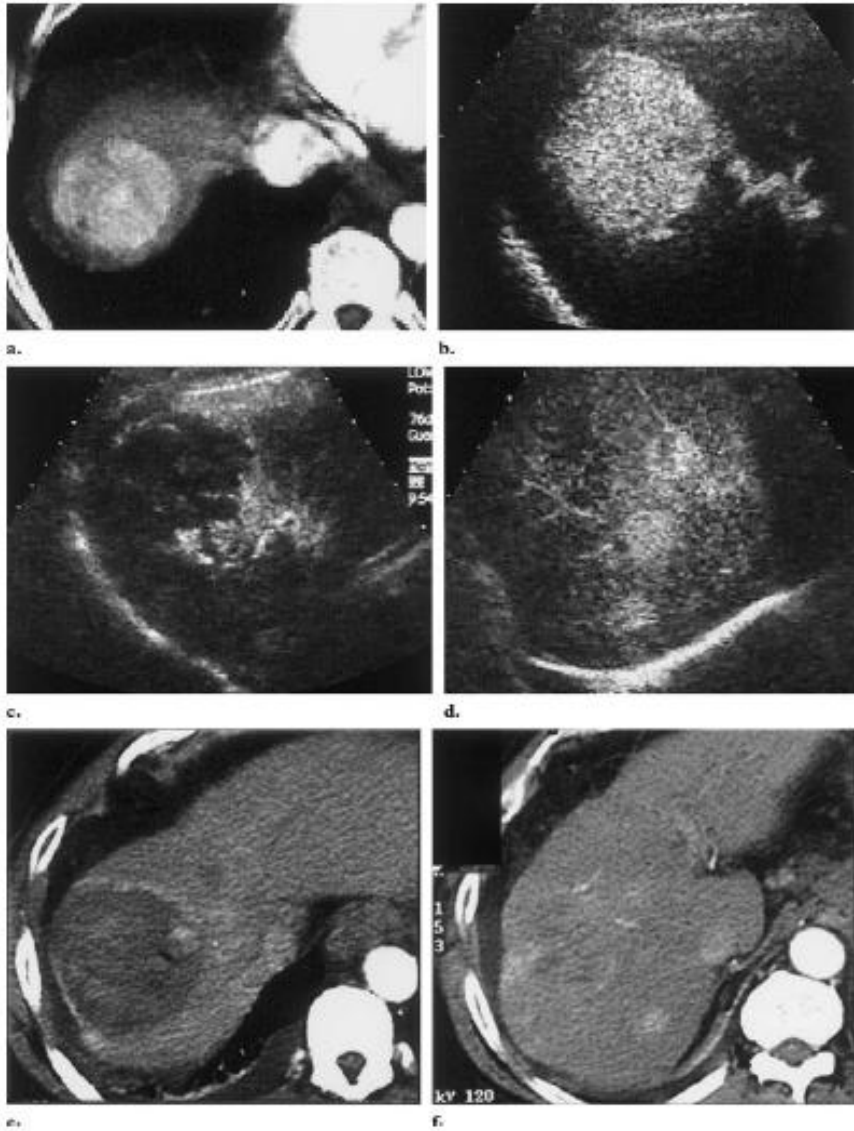


Figure 4 - Hepatocellular Carcinoma, with 5.5 cm in diameter, in a patient with 62 years of age. CT images pre-ablation (a) and ultrasound (b) obtained during the arterial phase, showing a hypervascular mass in segment 8 of the liver. Ultrasound contrast images postablation showed two small (1.8 cm and 1.2 cm in diameter) nodules of viable tumor tissue in the caudal portion of mass (c) and new small foci of hepatocellular carcinoma in segment 6 (d). Additional CT images show that the ablated area with small foci of residual tumor (e) and new recurrent nodules in the most caudal portion of the liver (f).

Source: Rhim, H. et al (2001). *Essential Techniques for Successful Radio-frequency Thermal Ablation of Malignant Hepatic Tumors*. Philadelphia. Elsevier

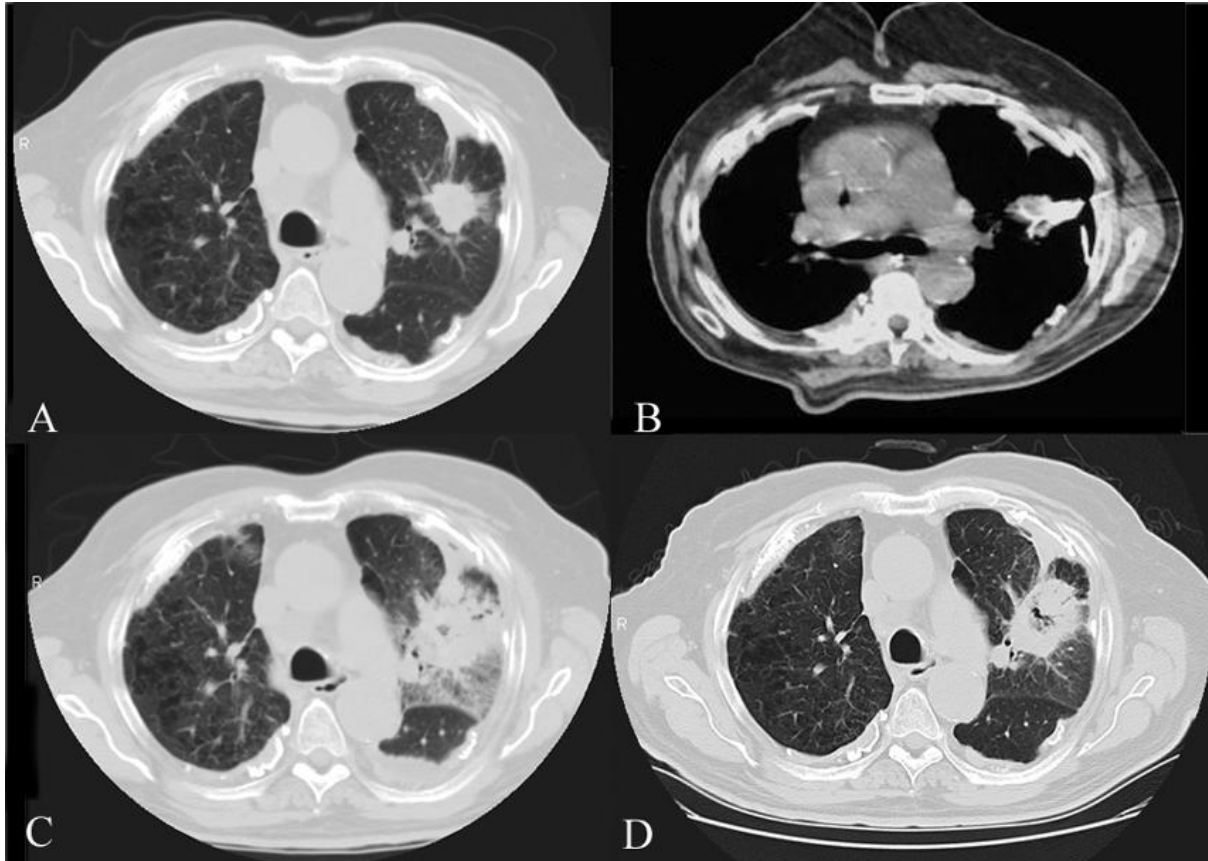


Figure 5 - Treatment with percutaneous RFA of a left non-small cells lung carcinoma in a patient of 78 years. (A) CT image before the procedure revealed a 3cm mass in the left upper lobe lung. (B) Treatment with RFA guided by CT image (C) CT image 2 days after RFA showing inflammation and hemorrhage. (D) CT 3 months after the procedure reveals a central cavity and reduced density of the lesion.

Source: Ellis, L., Curley, S., Tanabe, K (2004). *Radiofrequency Ablation for Cancer – Current Indications, Techniques, and Outcomes*. Nova York. Springer.

4. CONCLUSION

Radiofrequency ablation is now a generally accepted method for local tumor ablation and is used in benign and malignant tumors, primary and secondary. (Nicholson, 2009)

An RF of a tumor requires the induction of large volumes of coagulation necrosis. Changes in the deposition of RF energy and modulation of the biology of tumor or organ in question can significantly increase the volume of tissue thermal damage induced. (Nicholson, 2009)

Furthermore, the optimization of adjuvant strategies might allow better treatment of tumors clinically relevant. However, further studies are needed to determine under what conditions a particular method proves to be superior to another method and if any of these methods can improve the prognosis. (Nicholson, 2009)

The number of RF applications in a RFA procedure varies from patient to patient and depends on the size, shape and location (s) tumor (s). The procedure, in turn, depends on the number of RF applications. The imaging methods are essential to the practice of ARF and during the follow-up. (Nicholson, 2009)

The imaging technique is often chosen based on the preferences and experience of the operator. (Sonnenberg, 2005)

The radiographer should be familiar with the equipment, in particular CT and MRI, in order to best make a contribution will perform the procedure when the physician need to locate, access, monitor and control the damage before, during and after procedure.

In some aspects, the ARF is still a novelty, so it can provide great advances in this modality in the coming years.(Nicholson,2009)

5. REFERENCES

- Kaufman, J. Lee (2004), M. *Vascular and Interventional Radiology – The Requisites* .Philadelphia. Elsevier.
- Nicholson, T (2009). *Standards for Radiofrequency Ablation*. Royal College of Radiologists. Londres.
- Sonnenberg, E., McMullen, W., Solbiati (2005). *Tumor Ablation Principles and Practice*. Nova York. Springer.
- Vogl, T. J. et al (2008). *Percutaneous Tumor Ablation in Medical Radiology*. Nova York. Springer.